



Wound  
Ostomy and  
Continence  
Nurses  
Society

## **ASCRS and WOCN Joint Position Statement on the Value of Preoperative Stoma Marking for Patients Undergoing Fecal Ostomy Surgery**

The American Society of Colon & Rectal Surgeons (ASCRS) and the Wound Ostomy Continence Nurse Society (WOCN) recommend that all patients scheduled for ostomy surgery should have stoma marking done preoperatively by an experienced, educated and competent clinician.

A preoperative visit is preferred for the patient scheduled to have ostomy surgery for both assessment and education of the patient and their family about their future ostomy. Stoma site selection should be a priority during the preoperative visit. Marking the site for a stoma preoperatively allows the abdomen to be assessed in a lying, sitting and standing position. Evaluation in these multiple positions allows determination of the optimal site. This evaluation can help reduce postoperative problems such as leakage, fitting challenges, need for expensive custom pouches, skin irritation, pain and clothing concerns. Poor stoma placement can cause undue hardship and have a negative impact on psychological and emotional health. Proper placement of the stoma enhances patient independence in stoma care and resumption of normal activity. Furthermore, this preoperative visit allows the patient and their family to begin learning about stoma care and the use of ostomy appliances prior to surgery at a time when they are less distracted than in the immediate post-operative period.

Colon and rectal surgeons and ostomy nurses are the optimal providers to mark stoma sites, as this is a part of their education, practice and training. In cases where a colon and rectal surgeon or ostomy nurse is unavailable to perform stoma site marking, a trained clinician can perform the procedure.

Preoperative site markings are a guide, and are not necessarily the final surgical site. The final site selection is done by the surgeon once the abdominal cavity is entered and the condition of the bowel is determined.

ASCRS and WOCN have developed an educational guide to assist clinicians in performing this procedure.

Adopted by ASCRS Board 4.17.07

Approved by WOCN Board of Directors 5/17/07

# Stoma Siting Procedure

**Subject:** Stoma Siting Procedure

**Purpose:** Marking the site for a stoma preoperatively allows the abdomen to be assessed in a lying, sitting and standing position. Such an assessment allows the determination of the optimal site. This planning can help reduce postoperative problems such as leakage, fitting challenges, need for expensive custom pouches, skin irritation, pain and clothing concerns. Poor placement can cause undue hardship and impact psychological and emotional health. Good placement enhances the likelihood of patient independence in stoma care and resumption of normal activities.

Colon and rectal surgeons and ostomy nurses are the optimal providers to mark stoma sites, as this is a part of their education, practice and training. In cases where a colon and rectal surgeon or ostomy nurse is unavailable, the following procedure provides key points to consider when siting a stoma.

## Key Points to Consider

- Positioning issues: contractures, posture, mobility e.g. wheelchair confinement, use of walker etc.
- Physical considerations: large/protruding/pendulous abdomen, abdominal folds, wrinkles, scars/suture lines, other stomas, rectus muscle, waist line, iliac crest, braces, pendulous breasts, vision, dexterity, presence of hernia.
- Patient considerations: Diagnosis, history of radiation, age, occupation
- Other: Surgeon preferences, patient preferences, type of ostomy or diversion, anticipated stool consistency.
- Multiple stoma sites: Mark fecal and urinary stomas on different horizontal planes/lines.

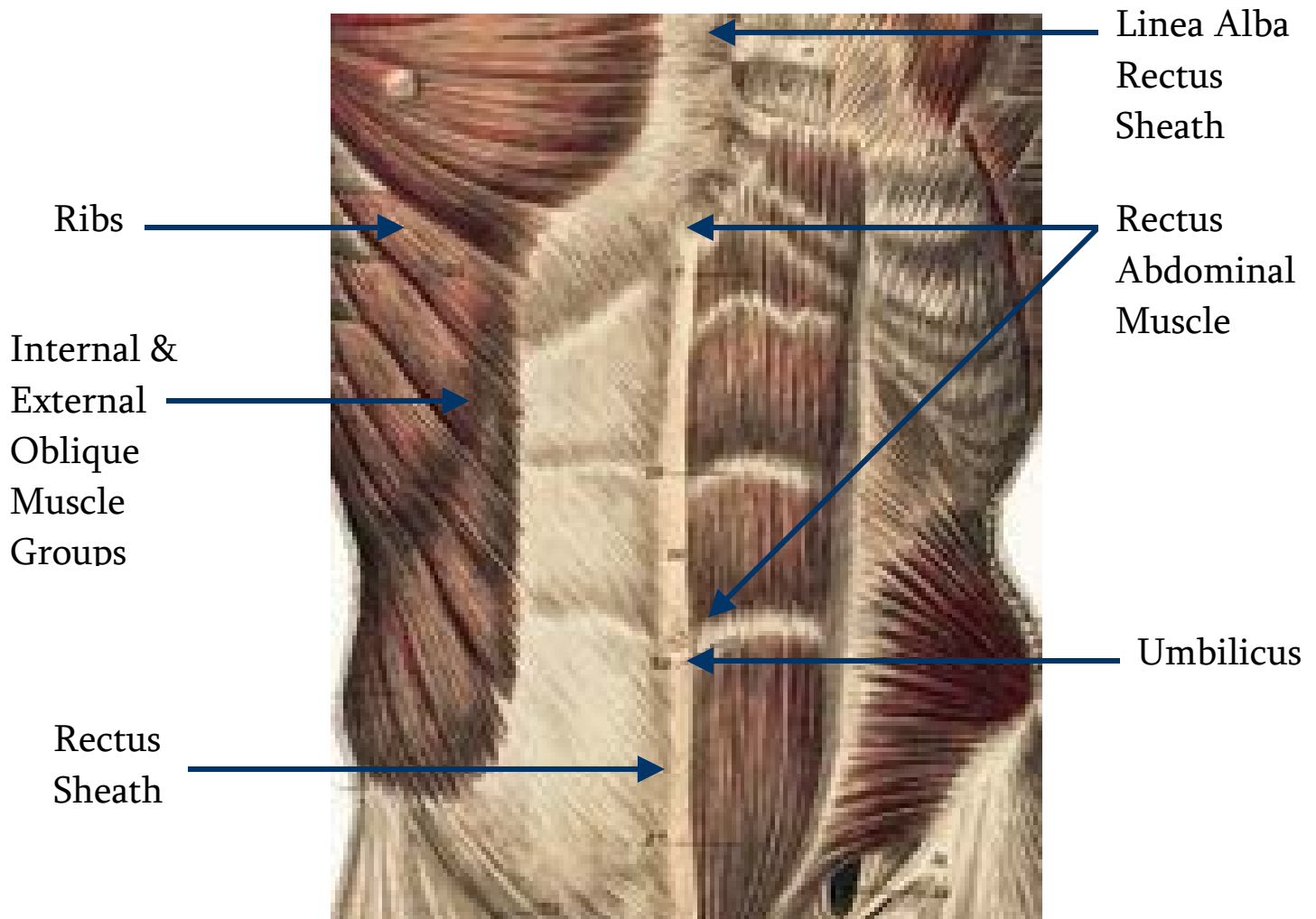
## Procedure:

1. Gather items needed for the procedure:
  - Marking pen, surgical marker, transparent film dressing, flat skin barrier (According to surgeon's preference and facility policy).
2. Explain stoma marking procedure to patient, and encourage patient participation and input.
3. Carefully examine patient's abdominal surface. Begin with patient fully clothed in sitting position with feet on floor. Observe the presence of belts, braces and any other ostomy appliances.

4. Examine patient's exposed abdomen in various positions (standing, lying, sitting and bending forward) to observe for creases, valleys, scars, folds, skin turgor and contour.
5. Draw an imaginary line where the surgical incision is going to be. Choose a point approximately 2 inches from the surgical incision where 2 – 3 inches of flat adhesive barrier can be placed.
6. With patient lying on back identify the rectus muscle. (This can be done having the patient do a modified sit up (raise the head up off the bed). Placement within the rectus muscle can help to prevent peristomal hernia formation and/or prolapse.

See picture below to identify desirable surface areas to mark:

## Anatomy



7. Choose an area that is visible to the patient, and if possible below the belt line to conceal the pouch.
8. If the abdomen is large, choose the apex of the mound or if the patient is extremely obese, place in the upper abdominal quadrants.
9. It may be desirable to mark sites on the right and left sides of the abdomen to prepare for a change in the surgical outcome (you may want to number your first choice as 1 #).
10. Clean the desired site with alcohol and allow to dry. Then proceed with marking the selected site with a surgical marker/pen. You may cover with transparent film dressing if desired to preserve the mark.
11. Once marked have the patient assume sitting, bending and lying position to assess and confirm best choice. It is important to have the patient confirm they can see the site.

*\*Anatomy Illustration provided by Hollister*

**Authors:**

Kathy Berry, BSN,RN,CWOCN; Jane Carmel, MSN,RN,CWOCN; Nancy Gutman, BSN,RN,CWOCN; Martha Link, BSN,RN,CWOCN; Barbara Markt, BSN,RN,CWOCN; Barbara Metzger, BSN, RN, CWOCN; Judith Morey, APN, RN,CWOCN; Molly Pierce, BSN,RN,CWOCN; Ginger Salvadalena, MN,RN,CWOCN

Amir, Bastawrous, MD; Gary Dunn, MD; C. Neal Ellis, MD; Neil Hyman, MD; Walter Koltun, MD; Ann Lowry, MD; Les Rosen, MD; Janice Rafferty, MD; Alan Thorson, MD; Eric Weiss, MD